


PATIENT

Tao Szymczak

PRESENTING CLINICAL SIGNS

History: Increased resp rate. Marked arrhythmia. Weight loss with decreased appetite. Previous history of retinal detachment, possible hypertension but not followed up.

SPECIES

Feline

ECHOCARDIOGRAM FINDINGS

2D, m-mode, color flow and doppler imaging is available. The left ventricular wall is normal with regions of remodeling and irregularity. There is a diffusely hyperechoic endocardium consistent with fibrosis. The systolic function is severely decreased with evidence of diastolic dysfunction as well. The papillary muscles are mildly remodeled. The left atrium is severely dilated. No obvious spontaneous contrast; no obvious thrombus. Trace central MR due to annular stretch. The right ventricle appears normal. No RA dilation. No TR. Blood flow through the RVOT and LVOT is low normal velocity. No pericardial effusion. Moderate volume pleural effusion. No obvious cardiac tumors. Marked tachycardia throughout.

BREED

DSH

SEX

Male Neutered

AGE

10 years

CARDIAC CHART
WEIGHT

10.8lbs

FELINE CARDIAC PARAMETERS	BODY WEIGHT (kg)	HR (BPM)	IVSd (cm) (Moise, Pipers)	LVIDd (cm) (Moise, Pipers)	LVWd (cm) (Moise, Pipers)	FS (%)	EF (%)
NORMAL PARAMETER	-----	150-240	0.35-0.55	<2 (mean 1.5)	3.5-0.55	35-67	80-100
PATIENT	4.92	>300	0.43	1.69	0.47	24	52
FELINE CARDIAC PARAMETERS	LA/AO (Boon)	LA/AO HEART BASE (Swe) (Abbott)	LA 2D short axis Base view (cm) (Abbott)	LVOT VEL (m/s)	RVOT VEL (m/s)	E max (m/s)	
NORMAL	<1.5	<1.3	<1.2	<1.6	<1.3	<0.9	
PATIENT	2.5	2.2	1.9	0.7	0.7	NM	
*Note: All measurements based upon multi-modal images and methods. An average value is reported. Adapted from June Boon, Veterinary Echocardiography, 1998 Abbott J & MacLean H JVIM 2006;20: 111-119, Moise et al. Am J Vet Res 47:1476, 1986. Pipers et al. Am J Vet Res 40:882, 1979.							

INTERPRETED BY

 Maggie Machen Lamy,
 DVM DACVIM
 (Cardiology)

IMAGING PERFORMED BY

Kelly Reschny, RVT

HOSPITAL NAME

 East Credit Veterinary
 Hospital

REFERRING VET

Dr. Webster

INTERPRETATION OF THE FINDINGS & FURTHER RECOMMENDATIONS

The finding of severe left atrial enlargement in the face of normal LV wall thickness and systolic dysfunction is most consistent with Restrictive Cardiomyopathy (RCM), however some historical infectious or inflammatory insult to the myocardium cannot be definitively ruled out. End-stage hypertrophic disease can also have this appearance, particularly given the history of systemic hypertension. Regardless, left atrial dilation is causing insufficiency of the mitral valve and systolic dysfunction has developed.

INVOICE

25691

DATE

8/10/22

The finding of severe left atrial dilation confirms the origin of the tachypnea and effusion is spontaneous congestive heart failure, and lifelong medications are warranted as below. A marked tachycardia is noted on the exam and throughout the study and an ECG should be assessed imminently. An uncontrolled tachycardia can cause acute decompensation and may also require therapy. If this cannot be done in your facility, immediate referral is advised. This patient is at high risk for thromboembolic events regardless of medications



PATIENT

Tao Szymczak

SPECIES

Feline

BREED

DSH

SEX

Male Neutered

AGE

10 years

WEIGHT

10.8lbs

INTERPRETED BY

Maggie Machen Lamy,
DVM DACVIM
(Cardiology)

IMAGING PERFORMED BY

Kelly Reschny, RVT

HOSPITAL NAME

East Credit Veterinary
Hospital

REFERRING VET

Dr. Webster

INVOICE

25691

DATE

8/10/22

and this should be expressed to the owner (monitor for neurologic change, acute paralysis/lameness, etc.). Consider hospitalization for continued stabilization, oxygen and Lasix therapy. A thoracocentesis should also be considered due to effusion and instability. The prognosis is poor to grave, with a mean survival time for cats with CHF <8-12 months, however most are able to maintain a good quality of life on medications if able to be stabilized. There will always remain risk for recurrent episodes of CHF, development of blood clots, arrhythmias, and/or sudden death in the future. Monitoring of sleeping breathing rates at home is recommended as the best way to screen for recurrent CHF at home.

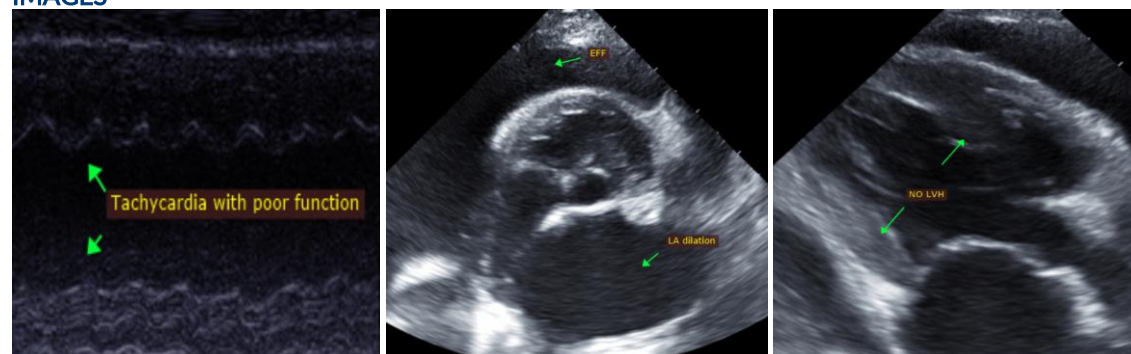
PLAN

Immediate ECG evaluation recommended. Consider thoracocentesis, hospitalization, oxygen, IV diuretic in hospital until stabilized due to effusion. Oral medications: furosemide 1-2mg/kg PO q12h. Institute blood thinner Clopidogrel (Plavix) 75mg tablets; give ¼ tab orally once daily (NOTE: this medication is very bitter on the cut edges). Institute Pimobendan (off label use) 0.625mg PO q12h.

Once stabilized, eating well at home and BP >130mmHg, consider addition of vasodilator ACE-I (benazepril or enalapril) 0.5mg/kg PO q12h.

Recheck renal values in 10-14 days to ensure tolerance of medications, then every 3-4 months lifelong. A recheck echocardiogram is recommended in 4-6 months to assess for progression.

IMAGES



The information and recommendations provided are based on the images presented by the referring veterinarian. No evaluation can be communicated regarding pathology that was not visible in the image/video clips provided.

Thank you for this referral. This report was generated using transcription software, and minor dictation errors may be present. If the clinical or image interpretation does not parallel your findings or if I can be of any further assistance, please contact me.

Maggie Machen Lamy, DVM
Diplomate of the American College of Veterinary Internal Medicine (Cardiology)
info@sonopath.com